

# Modification of the Zitelli Bilobed Flap

## A Comparison of Flap Dynamics in Human Cadavers

Michael Cho, MD; David W. Kim, MD

**Objective:** To investigate the effects on overall flap dynamics of altering the length of the primary flap in the Zitelli bilobed flap procedure, because the standard Zitelli design can result in distortion of the alar margin after repair of cutaneous nasal alar defects.

**Methods:** Identical 1.5-cm circular cutaneous defects were made on the nasal alae and cheeks of 6 fresh human cadavers. A rectangle was inked around each cheek defect in a standardized fashion. A standard-design Zitelli bilobed flap was used to close the nasal and cheek defects on 1 side of each specimen (n=6). The contralateral defect was closed with a modified design in which the primary flap was either 10% longer (n=3) or 10% shorter (n=3) than the standard primary flap as measured from the pivot point. Alar margin retraction and cheek defect distortion were

measured from standardized photographs obtained before and after the repair.

**Results:** The long-flap design resulted in alar retraction that was 1.33 mm less in the nasal reconstructions ( $P=.02$ ) and distal defect distortion that was 2.17 mm less in the cheek reconstructions ( $P=.01$ ) compared with the standard Zitelli bilobed flap. The short-flap design caused more distortion than did the standard design for both types of defect.

**Conclusion:** Lengthening the primary flap in the Zitelli bilobed flap design may reduce distal wound distortion and alar retraction in the closure of certain cutaneous defects.

*Arch Facial Plast Surg. 2006;8:404-409*

**S**INCE ESSER'S DESCRIPTION IN 1918,<sup>1</sup> the bilobed flap has been a workhorse technique to repair small to moderate-sized cutaneous nasal defects. Esser's design used 2 flaps of equal size at 90° and 180° from the axis of the defect. In 1953, Zimany showed that the second lobe could be made smaller than the first while facilitating closure.<sup>2</sup> Zitelli<sup>3</sup> made the most recent modification

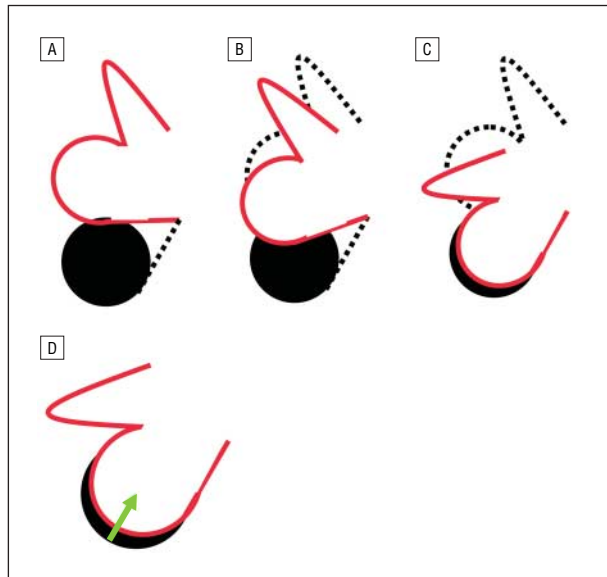
sidewall. By recruiting this lax tissue, the design allows for a closure that has lower tension overall. The excellent vascularity of this flap makes it an ideal reconstructive option for simple nasal and cheek lesions less than 1.5 cm in diameter.<sup>4</sup>

One disadvantage of the Zitelli bilobed flap is a reported 5% complication rate of alar retraction.<sup>5</sup> These complications are likely due to excessive tension on closure of the primary lobe and distal defect. Tension at the distal wound edge may be attributed to Dzubow's principle of pivotal restraint, which states that any flap transposed or rotated around a pivot point will be tethered at the base of the pedicle.<sup>6</sup> Thus, as the flap rotates toward the defect, the distance from the original pivot point to the distal part of the flap decreases. This effective shortening of the flap causes a gap between the distal aspect of the defect and the tip of the flap. This remaining distance must then be spanned by a combination of further stretch and mo-

*See also page 410*

by adjusting the rotational angles to 50° each, to decrease the buckling around the pivotal point and the distal distortion that occurs with the previous bilobed designs. The Zitelli bilobed flap rotates from a medial pivot point for alar defects and from a lateral pivot point for tip defects. The second lobe typically extends to the loose skin of the upper dorsum and nasal

**Author Affiliations:** Division of Facial Plastic Surgery, Department of Otolaryngology–Head and Neck Surgery, University of California, San Francisco.



**Figure 1.** Effect of pivotal restraint on the Zitelli bilobed flap design. The solid circle (A-D) is the defect intended for reconstruction. The dotted lines (A-C) represent deeper incisions. The red lines (A-D) are the edges of the flap being transposed. The green arrow (D) shows the directional force of pivotal restraint on the flap.

bilization of the flap itself, additional undermining around the pedicle base, and advancement of the distal edge of the defect toward the flap (**Figure 1**). In some cases, the advancement of the distal edge of the defect may cause unwanted distortion of neighboring anatomic landmarks. In nasal reconstruction with a standard Zitelli bilobed flap, this may lead to alar retraction caused by advancement of the distal defect. Dzubow's principle reminds us that standard flap design may fail to perform as expected when planned only from 2-dimensional geometric principles.

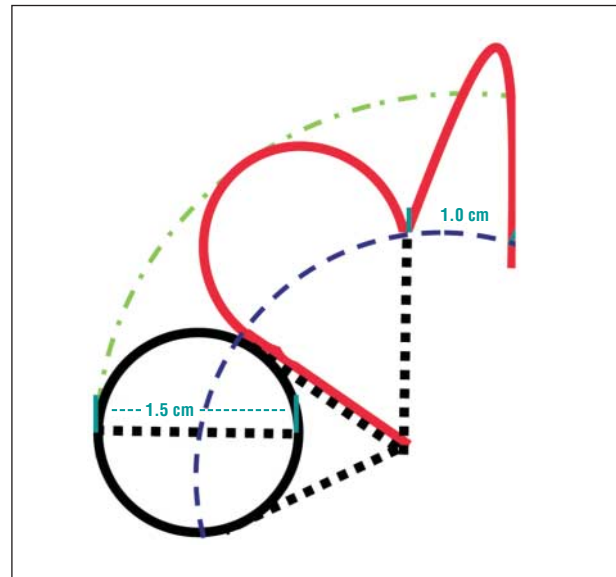
To compensate for pivotal restraint, we modified the Zitelli bilobed flap to have a longer primary lobe. Theoretically, this extra flap length would reduce or eliminate tension at the distal defect edge because it compensates for the shortening of the effective flap length with rotation. We performed this modified flap on fresh cadavers to test the effects of this modification on the tension and distortion of the alar rim and cheek tissue in cutaneous reconstruction.

## METHODS

Six fresh cadaver heads were obtained from the Department of Anatomy at the University of California, San Francisco. An aluminum foil template was used to create standardized bilateral 1.5-cm circular cutaneous cheek and alar defects. The defects were sharply excised to a subcutaneous level.

### NASAL STUDY

The 1.5-cm circular cutaneous defects were created 5 mm above the midpoint of the alar rim bilaterally for each nose. On one side of each cadaver nose, a standard-design Zitelli bilobed flap was used to close the defect (n=6). The primary rotational flap was equal in length to the defect itself as mea-

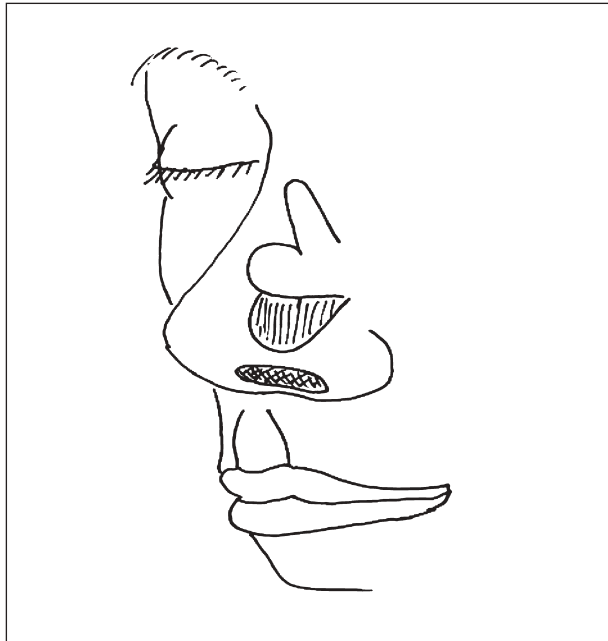

**Figure 2.** Illustration of the standard Zitelli bilobed flap design.



**Figure 3.** Templates used for long (top), short (bottom), and standard (center) Zitelli bilobed flap design. The ruler indicates centimeters.

sured from the pivot point (2.25 cm) (**Figure 2**). The opposite side of each cadaver nose had a long-flap (n=3) or short-flap (n=3) modified design. The long-flap design had a 10% longer primary lobe (2.5 cm); the short-flap design had a 10% shorter primary lobe (2 cm). The length of the secondary lobe was 150% of the defect length for all reconstructions. The width of the primary lobe was equal to the width of the defect (1.5 cm), and the width of the secondary lobe was two thirds the width of the primary lobe (1.0 cm) for all reconstructions. Preformed foil templates were traced onto the noses for uniformity (**Figure 3**). In all cases, the orientation of the flap design was the same, with the axis of the secondary lobe pointing superiorly toward the radix (**Figure 4**). The defects were undermined in the submuscular plane, just superficial to the perichondrium and periosteum of the nasal skeleton, laterally to the premaxillary border, superiorly to the nasion, medially to the midline, and inferiorly to the alar rim. We placed 5-0 polyglactin 910 tacking sutures in a full-thickness interrupted fashion to reapproximate the defects. The needle bites were placed 3 mm from the skin edges, and sutures were spaced 5 mm apart. Before and after closure, lateral photographs were obtained perpendicular to the defects at a uniform distance of



**Figure 4.** Orientation of the standard Zitelli bilobed flap design on the nasal sidewall.

0.6 m away using a digital camera (S5i Optio; Pentax Imaging Co, Golden, Colo) and a force flash setting (ISO 200, automatic shutter speed).

Digital photographs were analyzed with Adobe Photoshop, version 8.0 (Adobe Systems, San Jose, Calif). From the lateral view, the width of the defect (1.5 cm) was used to establish a standard against which other measurements could be made. On magnified images of the alar margin, a straight line was inserted between the anteriormost and posteriormost points of the inner rim of the nostril. As described by Gunter,<sup>7</sup> this line represents a reference marker from which the degree of alar retraction may be measured. We refer to this line as the “equator” of the nostril. The distance from the nostril equator at the highest point of the alar margin was measured in each of the preoperative and postoperative photographs to the nearest 0.5 mm (**Figure 5**). The difference in these values represented the degree of alar rim retraction caused by the reconstruction.

### CHEEK STUDY

We created 1.5-cm circular cutaneous defects on each cadaver cheek bilaterally, with the superior medial corner of the template on the lateral orbital rim and the horizontal limb parallel to the Frankfurt horizontal plane. These were closed with a standard-design Zitelli flap on one side and either a long-flap (n=3) or short-flap (n=3) design on the other side, using the same dimensions as in the nasal study. Before dissection of the bilobed flaps, a standardized 5.5×6-cm rectangle was inked around each pattern, with one edge 5 mm from the distal defect and oriented with the long axis perpendicular to the vector of maximal tension (**Figure 6A**). Undermining was limited to the area inside the inked rectangle. As before, standardized preoperative and postoperative photographs were obtained.

Adobe Photoshop was used to assess tissue distortion as measured by the distance of movement on the edge of the rectangle nearest the distal defect. The preoperative and postoperative photographs were superimposed, using the superior

rectangular limb as the reference line. We then measured the distance between the lines forming the distal sides of the bordering rectangles at their point of greatest divergence to represent the distortion of the distal defect (**Figure 6B and C**).

## DATA ANALYSIS

Preoperative and postoperative measurements were compared using a paired *t* test on the StatView program (1998 version; SAS Institute Inc, Cary, NC). Results are presented as mean±SD unless otherwise indicated.

## RESULTS

### NASAL STUDY

The long-flap design resulted in  $0.5 \pm 0.5$  mm of alar retraction compared with  $1.83 \pm 0.57$  mm of retraction on the contralateral normal-length flaps. The long-flap design had less nasal alar retraction than did the standard Zitelli flap by a mean difference of 1.33 mm ( $P = .02$ ). The short-flap design resulted in  $3.33 \pm 1.26$  mm of alar retraction compared with  $1.5 \pm 0.5$  mm of retraction on the contralateral side. The short-flap design, therefore, resulted in more alar retraction than did the standard flap by 1.88 mm, which approached statistical significance ( $P = .09$ ) (**Figure 7**). The average alar retraction for each reconstruction is also seen in **Figure 7**.

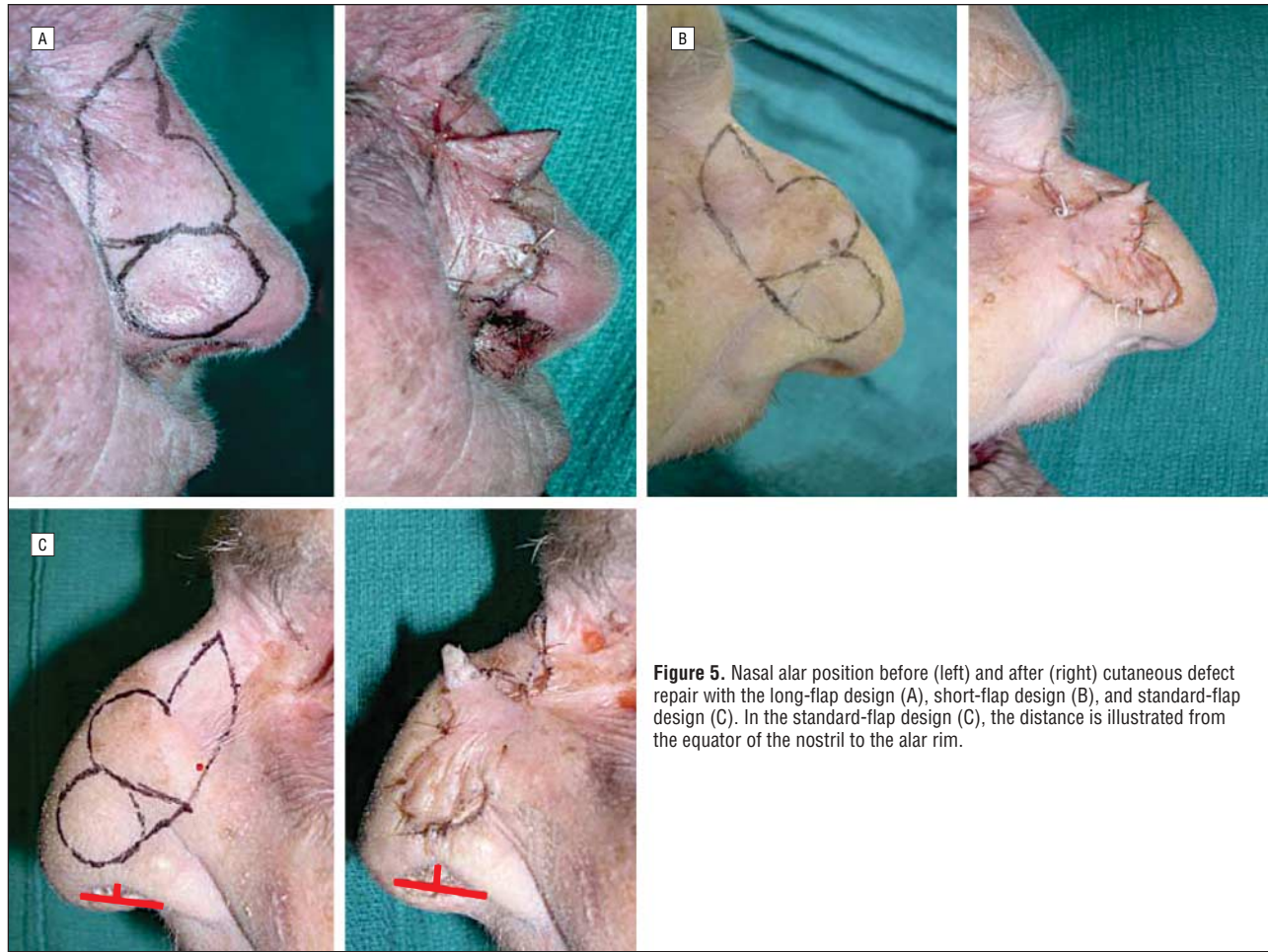
### CHEEK STUDY

For the cheek defect, the long-flap design resulted in movement of the distal marked border of  $0.17 \pm 0.29$  mm compared with  $2.33 \pm 0.29$  mm in the contralateral standard flap design. Therefore, the longer flap led to a distal defect pull that was 2.17 mm less ( $P = .01$ ) compared with the standard flap. The shorter flap resulted in distortion of the distal marked border of  $3.5 \pm 1.0$  mm compared with  $1.5 \pm 0.5$  mm of retraction in the contralateral standard-length flaps. Thus, the shorter flaps resulted in 2.0 mm more retraction than did the standard flap, although this difference was not statistically significant ( $P = .12$ ) (**Figure 8**).

## COMMENT

The Zitelli bilobed flap has been described for defects of the lower third of the nose that are 1.5 cm in diameter or smaller. Unfortunately, because of loss of length with transposition, use of this flap can lead to alar retraction, which some have proposed to bypass by lengthening the flap.<sup>8</sup> We hypothesized that a longer primary flap would decrease distal wound tension and alar retraction. By performing this cadaver study, we found a significant difference in photographic measurements of alar retraction and distal wound distortion. Thus, our modification to the classic Zitelli bilobed flap may improve overall cosmesis in nasal reconstruction in selected cases.

The bilobed flap has many advantages over other flaps. The design is simple and the surgical technique is straight-



**Figure 5.** Nasal alar position before (left) and after (right) cutaneous defect repair with the long-flap design (A), short-flap design (B), and standard-flap design (C). In the standard-flap design (C), the distance is illustrated from the equator of the nostril to the alar rim.

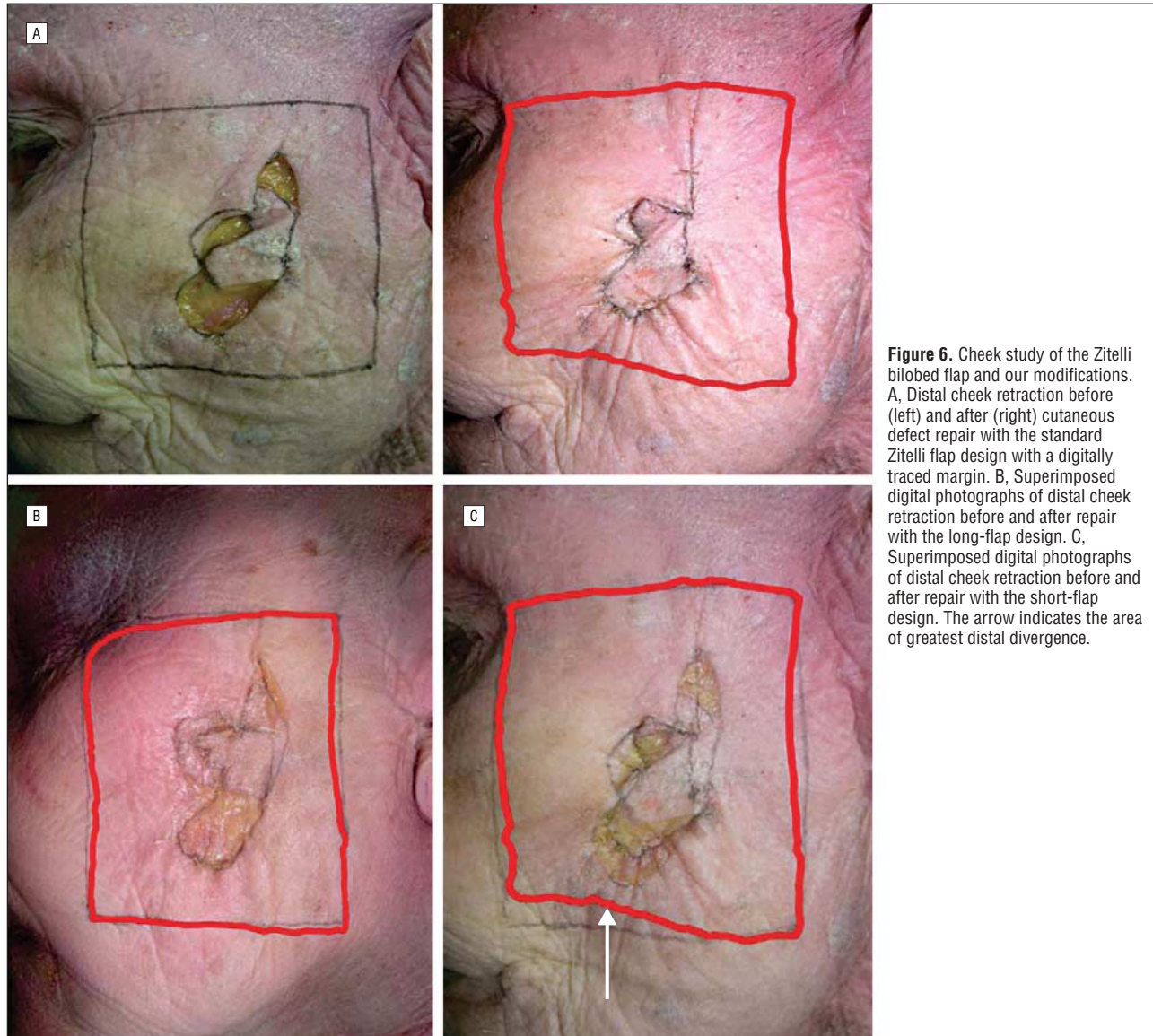
forward. In addition, it produces excellent color and texture match with adjacent tissue. Because it is a single-stage procedure and uses tissue from within the nose, it is a better choice for small to medium-sized nasal defects than a 2-staged paramedian flap. A dorsal sliding flap may result in a relatively low-tension closure but generally requires a much larger incision. Other single-transposition flaps such as rhomboids are less effective in the lower third of the nose, in which the tight skin limits flap rotation and tends to cause more tissue protrusion around the pivot point.

The main reported disadvantages of the Zitelli bilobed flap are distal flap tension resulting in retraction and pincushioning. It is our opinion that this distal tissue retraction and distortion is a result of pivotal restraint. The rotation of the bilobed flap causes effective shortening of the flap, creating a gap that must be spanned by the distal edge of the defect. Our study shows that lengthening the primary flap in the Zitelli design may compensate for this expected gap and allow for less tension at the distal wound edge. Such a closure would prevent distal retraction (Figure 1) and reduce anatomic distal distortion.

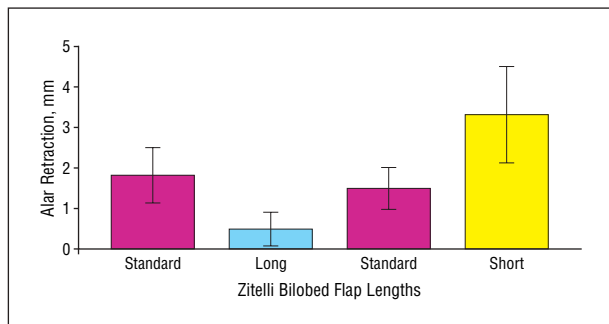
Before applying the modified Zitelli bilobed flap in nasal reconstruction, one must consider the quality of

the individual's nasal skin. In patients with very thick, stiff skin, there may be a tendency of local flaps to create a "bulldozing" effect, in which downward displacement of the alar margin results from the bulk of the primary flap pushing caudally.<sup>1</sup> In such cases, it is likely that some degree of pivotal restraint occurs, but this restraint is counteracted by a caudally oriented pushing effect by the thick primary flap. In these situations, the nostril margin not only may become displaced inferiorly but its normally arched contour may become distorted. Therefore, when using the long-flap modified Zitelli design, we recommend assessing the alar margin position and contour after the first few anchoring sutures are placed when inseting the primary flap. If downward displacement or distortion ensues, the surgeon may cut these sutures to release the flap and then incrementally trim the flap until a satisfactory alar position and contour is achieved. Because the flap can be trimmed but not lengthened once it is incised, the surgeon should start with a longer flap. This technique will allow the surgeon to create an ideal primary flap length that is suited to the individual defect, skin type, and local anatomy.

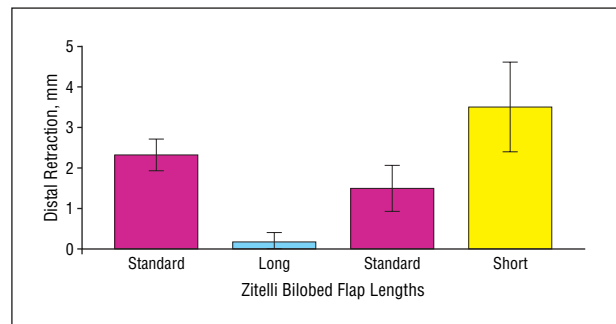
Our use of cadavers provided an internal control in the experimental reconstructions because we were able



**Figure 6.** Cheek study of the Zitelli bilobed flap and our modifications. A, Distal cheek retraction before (left) and after (right) cutaneous defect repair with the standard Zitelli flap design with a digitally traced margin. B, Superimposed digital photographs of distal cheek retraction before and after repair with the long-flap design. C, Superimposed digital photographs of distal cheek retraction before and after repair with the short-flap design. The arrow indicates the area of greatest distal divergence.



**Figure 7.** Mean  $\pm$  SD nasal alar retraction comparing short- and long-flap groups with contralateral standard-length groups.



**Figure 8.** Mean  $\pm$  SD distal defect retraction comparing short- and long-flap groups with contralateral standard-length groups on cadaver cheeks.

to compare the 2 sides. However, certain disadvantages were also apparent. First, it was impossible to determine the effect of healing and scar contracture on the reconstructions. These results cannot account for how the scar will eventually settle. This is of particular relevance to the pincushioning phenomenon that may be accen-

tuated with excess laxity in the bilobed flap. The rigor mortis that occurs with cadaver tissue also may have affected tissue pliability and our Zitelli bilobed flap modification. Finally, small facial asymmetries in these cadavers and the lack of uniformity between cadavers may have affected our data.

In conclusion, the current results provide preliminary evidence that the use of a long-flap modification of the Zitelli bilobed flap design may reduce distal tissue distortion in certain cases. The clinical effectiveness will be determined by future studies with long-term follow-up on human patients undergoing nasal reconstruction with this technique.

**Accepted for Publication:** August 8, 2006.

**Correspondence:** David W. Kim, MD, Division of Facial Plastic Surgery, Department of Otolaryngology–Head and Neck Surgery, University of California, San Francisco, 2330 Post St, San Francisco, CA 94115 (dkim@ohns.ucsf.edu).

**Financial Disclosure:** None reported.

## REFERENCES

1. Cook JL. A review of the bilobed flap's design with particular emphasis on the minimization of alar displacement. *Dermatol Surg.* 2000;26:354-362.
2. Burget GC, Menick FJ. *Aesthetic Reconstruction of the Nose.* St Louis, Mo: Mosby-Year Book Inc; 1994:134-151.
3. Zitelli JA. The bilobed flap for nasal reconstruction. *Arch Dermatol.* 1989;125:957-959.
4. McGregor JC, Soutar DS. A critical assessment of the bilobed flap. *Br J Plast Surg.* 1981;34:197-205.
5. Moy RL, Grossfeld JS, Baum M, Rivlin D, Eremia S. Reconstruction of the nose utilizing a bilobed flap. *Int J Dermatol.* 1994;33:657-660.
6. Dzubow LM. The dynamics of flap movement: effect of pivotal restraint on flap rotation and transposition. *J Dermatol Surg Oncol.* 1987;13:1348-1353.
7. Gunter JP. Facial reconstruction using local skin flaps. *J Otolaryngol.* 1978;7:171-182.
8. Murakami CS, Odland PP. Bilobed flap variations. *Oper Tech Otolaryngol Head Neck Surg.* 1993;4:76-79.

### Announcement

Visit [www.archfacial.com](http://www.archfacial.com). As an individual subscriber, you may elect to be contacted when a specific article is cited. Receive an e-mail alert when the article you are viewing is cited by any of the journals hosted by HighWire. You will be asked to enter the volume, issue, and page number of the article you wish to track. Your e-mail address will be shared with other journals in this feature; other journals' privacy policies may differ from *JAMA & Archives Journals*. Sign up to receive an e-mail alert when articles on particular topics are published.